

HISTOPATHOLOGICAL STUDIES ON ULCERATED FISH FROM THE BATTICALOA LAGOON

P.Vinobaba and M Vinobaba

Department of Zoology, Faculty of Science, Eastern University,
Sri Lanka

ABSTRACT

A disease similar to the epizootic ulcerative syndrome(EUS) made first appearance in Queensland, Austarlia. From 1979, EUS has spread throughout the South and Southeast Asia and has become a serious problem in fresh and brackish water fisheries. The ulcer disease on fish appeared regularly after heavy rain fall each year since then. The fish species viz. *Nematalossa* (koi-T), *Mugil cephalus* (manalai-T), *Siganus linetaus* (oora-T), *Signaus javus* (oddi-T), *Siganus virgatus* (oddi-T), *Siganus oramin* (vell oddi-T) *Sphyranea* (seela-T), *Tylosurus* (mural-T), *Sillago* sp.(killakan) and *Pertica* sp.(thirali-T) were shown to have ulcers generally on the dorsal surface from the brackish water area closer to the bar mouth and *Puntius* sp.(peddiyan-T) from the Sooruvamunai and Kakkudah (southern edge) of the lagoon.

The ulcers developed in different fish species were examined during the epidermics in 1990 and in March 1994 and again very recently in December 2001 when the signs of this disease was noted in *Puntius* sp belonging to the southern part of the lagoon. The study was conducted to identify the possible causative agent for the ulcers and associated histopathological studies on the affected fish. Light microscopic and scanning electron microscopic studies revealed the presence of fungal growth on the surface. Histological studies of *Signaus* sp. and *Nematalossa* sp. have shown that early stages small haemorrhagic lesions appeared in epidermis, dermis and

hypodermis. Subsequently localized lesions appeared in and progressed towards the other parts of fish body and expanded into large ulcers. The etiology of the ulcer primarily due to the presence of fungi and may be enhanced further by the presence of the ecto-parasitic organisms (*Trichodina* sp.)

INTRODUCTION

There has been out breaks of severe ulcerative condition of the wild fish in 1989 after heavy monsoon rains. Since from then the Batticaloa lagoon based fishery was severely affected by the unknown ulcerative disease after the rainfall each year (Vinobaba and George, 1996). The ulcerative condition affects the fishermen's socio- economic status by lowering the market value for fish during the disease season (Vinobaba and Vinobaba, 1999). It appeared first in 1989 in the eastern province after heavy monsoon rains. This ulcerative disease appears after heavy rainfall each year. The full time fishermen families were affected very badly.

The fish disease and associated fish kills considered to be a continuous problem for the Batticaloa lagoon. There has been no records and proper research done in the areas of fish disease and water quality of the lagoon. During the period of disease occurrence the value for the fish at the market showed a decline. Due to lowering market value to fish at the market has affected the fishermen's socio economic status. The water quality seems to vary form year to year and within the months of the year. During wet season the freshwater influx reduces the salinity of the lagoon water. Such reductions cause stress to fish and are easily succumb to disease and finally death. Not only salinity but also the oxygen concentration, pH etc varied with period therefore the records of water quality parameters are of utmost important.

Clinically, the disease starts as tiny spots or lesions on the body surface of the affected fishes. The lesion may develop as necrotising dermatitis and become ulcers characteristics of EUS

(Callinan *et al.*, 1989). The disease cause large scale mortality of affected fishes in a short period of time and affects a wide host range (Roberts *et al.*, 1993). Viruses (Frerichs *et al.*, 1986; Ahne *et al.*, 1988), bacteria (Llobreraa and Gacutan, 1987; Callinan and Keep 1989; Ali and Tamuli, 1991; Chakarabarty and Dastidar, 1991) and recently fungi (Callinan *et al.*, 1989 Roberts *et al.*, 1993) have been found to be associated with the disease, however the precise primary etiology of the disease is unclear. The sequence of disease development, mode of transmission and the role of various pathogens and the factors, which predispose the fish to the disease, are largely unknown. Some success, however, has recently been achieved in reproducing the disease under laboratory conditions (Roberts *et al.*, 1993). This present study was aimed to identify the possible causative agent for the ulcers and associated histopathological studies on the affected fish.

MATERIALS AND METHODS

Live fish (moribund fish) from different locations such as Palameenmadu, Kallady, Koddamunai, Pillayaradi, Sathurukondan, Eravur, Kiddanki, Kallar, Periyakallar of the Batticaloa lagoon were obtained at regular interval, biweekly.

Fish were brought to the temporary fish holding facilities at the District Fisheries Extension Office (DFEO) and left in the aquarium containing the water from the same location of the lagoon. Aeration was supplied continuously. The fish were investigated on the same day. The sampling was done in biweekly intervals through out the study period. Parasitic and pathological survey was carried out at each sampling time and also the isolation of pathogenic organisms was also done when it was necessary.

These parasites were observed in wet mounts and identified up to the generic level. Dissected out the superficial lesions and fixed immediately in cooled cocadylate buffer for electron microscopy and in buffered formaline for light microscopic

histological sectioning, along with the fixation of internal organs in buffered formaline (such as gills, gut, liver, spleen, kidney, muscles etc) for histological sectioning.

The above fixed specimens were transferred to the Institute of Aquaculture, University of Striling where histological sectioning and electron microscopic work were carried out.

RESULTS

The fish species viz. *Nematalossa*, *Mugil cephalus*, *Siganus linetaus*, *Signaus javus*, *Siganus virgatus*, *Siganus oramin*), *Sphyranea* sp., *Tylosurus* sp., *Sillago* sp. and *Pertica* sp. were shown to have ulcers generally on the dorsal surface from the brackish water area closer to the bar mouth and *Puntius* sp. from the southern edge of the lagoon.

The parasites such as *Trichodina* sp., *Trichodennela* sp, *Ichthyophthirius* sp., *Ergasilus* sp., were identified in the ulcerated fishes. The pathological features observed in all fishes collected from different sites were very similar and consistent. Large number of broad non-septate highly invasive fungal hyphae were associated with severe ulcers of *Nematalossa*, *Mugil cephalus*, *Siganus linetaus*, *Signaus javus*, *Siganus virgatus*, *Siganus oramin*), *Sphyranea* sp., *Tylosurus* sp., *Sillago* sp. and *Pertica* sp. In early lesions, the fungal hyphae were associated with severe necrosis of the epidermis and dermis. Acute spongiosis of the epithelium accompanied with an intense inflammatory response. In advanced lesions, massive invasion of fungal hyphae into the skeletal musculature was observed along with myofibrillar necrosis. The fungal hyphae were also observed in the epidermis and dermis, away from the dermal ulceration. Later, lesions continued to show mild epithelial necrosis, surrounding odema, hameorrhage of underlying dermis and inflammatory cell infiltration. Advanced lesions showed massive necrotizing granulomatous mycosis of underlying muscle fibers. Where as *Tylosurus* sp. showed disruption of the normal tissue with water logged tissues with

normal muscular tissue with the higher degree of cellular infiltration. Blood vessels of *Tylosurus* sp seem to have abundant cell logged inside the blood vessels (congested blood vessels). *Siganus* sp *Nematalossa* sp and *Sphyranea* sp showed similar pathology. Only in extreme cases in *Siganus* sp and *Nematalossa* sp. the fungal hyphae penetrated deeply into the kidney but such deep invasion of invasive fungus mycelium was not observed in other fin fish species.

Chronic inflammation leading to granulomatous response in the dermis and musculature was evident. Depending on the stage of the disease, large numbers of early to mature granuloma with fungal hyphae in the center could be clearly seen in the dermis and musculature. Fungal hyphae were invariably invested in a thick layer of chronic inflammatory tissue mainly consisting of host macrophages, epitheloid cells and fibroblasts. Some areas showed evidence of granuloma with progressive healing.

The host macrophage response was well organised with fibroplasias and the macrophages appeared to play a vital role in the granulomatous response in all the species of infected, ulcerated fish examined for this study. Apart from the tip of the mycelium, the mycelium inside the granuloma appeared dead with autolysed cell contents.

There were no histological evidence of bacterial associated tissue necrosis in the dermis and skeletal musculature. Smears and scanning electron micrographs showed the consistent presence of non-septate and branching fungal hyphae.




Fig 1: The photograph of *Siganus virgatus* with ulceration on the lateral side.




Fig 2: Photograph of *Nematalossa nasus* with ulceration on the lateral side.



Fig 3: Scanning electron micrograph showing the fungal growth of the dorsal surface of the *Nematalossa nasus* x 320

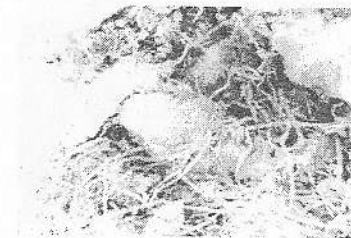


Fig 4: Scanning electron micrograph showing the fungal growth of the *Nematalossa nasus* next to the dorsal fin surface x 640

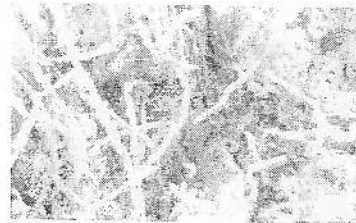

Fig 5: Scanning electron micrograph showing the fungal growth of the next to the dorsal fin surface of *Mugil cephalus* x 640



Fig 6: Scanning electron micrograph showing the fungal growth of the next to the ulcerated surface of *Sphyranea* sp. x 1200

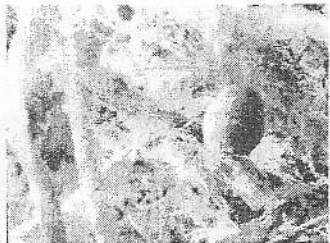

Fig 7 : Scanning electron micrograph showing the fungal growth closer to ulceration of *Siganus linetaus* x 3000



Fig 8 : The photomicrograph of the T.S of skin of *Siganus linetaus* showing the fungal invasion and associated necrosis and dermatitis (H&E x 100)

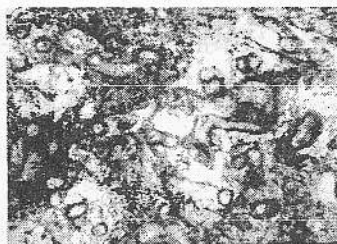


Fig 9 : Photomicrograph of a longitudinal section of a broad non-septate fungal hyphae in the muscles of *Nematalossa nasus* (H&E x 400)

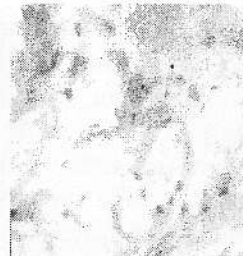

Fig 10 : Photomicrograph showing early ulcer with fungal hyphae surrounded by granulomatous tissue in skeletal musculature of *Mugil cephalus* (H&E x 1000)

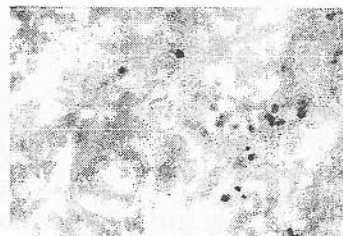


Fig 11 : Photomicrograph showing fungal hyphae invested in host inflammatory tissue besides the epidermis and dermis of *Mugil cephalus* (H &E x 1000)

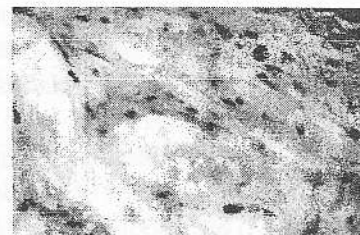


Fig 12 : Photomicrograph showing the inflammatory tissue consisting of host macrophages and connective tissue fibroblasts investing the fungal hyphae in *Nematalossa nasus* (H&E x 1000)

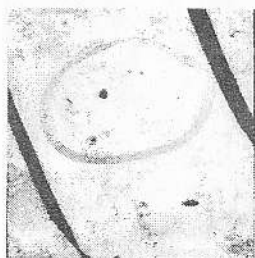

Fig 13 : Transmission electron micrograph showing the fungal hyphae in musculature of *Mugil cephalus* x 720

DISCUSSION

The ulcerative conditions are common problem in fish culture practices, especially in intensive farming systems. Epizootic ulcerative syndrome (EUS) is one such disease characterized by deep ulcers over the body surface. It has been shown to be a complicated disease and many pathogens have been observed in affected fish. Epizootic ulcerative syndrome (EUS), was defined at a regional seminar in Bangkok in 1994 as "a seasonal epizootic condition of freshwater and estuarine warm water fish complex infectious aetiology characterized by the presence of invasive *Aphanomyces* infection and necrotising ulcerative lesions typically leading to granulomatous response" (Robert *et al*, 1993). The same features were observed in the presented study with ulcerated fish from the Batticaloa lagoon. The same disease has been given various names at various countries, but it is most commonly known as mycotic granulomatosis (MG) in Japan, red spot disease (RSD) in Australia and epizootic ulcerative syndrome (EUS) in Southeast and South Asia. MG, RSD and EUS have, in the past, been described separately as distinct conditions, however, recent studies shown that the involvement of *Aphanomyces* fungus in each case and now it is apparent that all are the same (Vinobaba and Vinobaba, 1999). The histological sections revealed the presence of fungi

in this study. Only relatively few reports confirmed the presence of mycotic granulomas in histological sections. Some commercially important species are considered to be particularly resistant to EUS. Chinese major carps, tilapias and milk fish have not been affected. Some authors have commented that the most severely affected species in natural outbreaks are generally bottom dwellers (Lolbrera and Gacutan, 1987) or possess air breathing organ (Robert *et al*, 1994) in this present study the fish of different habitat showed the same symptoms.

The disease showed marked seasonality. Red spot was reported to spreading to New South Wales in 1974 to Western Australia in 1985 and northern territory in 1986. In 1975 a disease with similar clinical disease was observed in river systems in Papua New Guinea where several species of freshwater and estuarine fish such as mullet and gudgeon were affected. The species most severely affected was *Trichogaster*. Apart from this snakeheads, climbing perch, barbs, spiny eels and cat fish were subsequently affected. The same disease first appeared in 1981 in southern part of Thailand. The disease spread to the central part in 1982. It became the most serious epizootic in Thailand. Snakeheads are particularly susceptible species and they are widely farmed in central Thailand. While Thailand suffered with this disease there were reports of similar disease epizootic from Lao, Vietnam and Myanmar. There were no reports of disease outbreaks in Philippines until 1985, when the disease reported in brackish and freshwater species.

Although there had been serious outbreaks of a new severe and ulcerative condition of wild and farmed freshwater fish in Asia for almost a decade, there was a wide range of conflicting views as to its cause (Robert *et al*, 1994). Of particular concern was the possibility that it might be due to toxic effects of pesticides used in modern rice culture, but other suggested cause include bacteria, fungi and viruses.

It appeared first in 1989 in the eastern province after heavy monsoon rains. This ulcerative disease appears after heavy rainfall each year. The full time fishermen (the income is absolutely from fishing) families were affected very badly.

Nematalossa, *Mugil cephalus*, *Sphyranea*, *Tylosurus* and *Pertica* were shown to have ulcers on the dorsal surface. When ulcers from natural disease outbreaks were observed and it used to be associated with fungal growth may be saprophytic or pathogenic in nature. Since the same saprophytic water moulds are prevalent in a lagoon ecosystem can gain entry into the healthy fish body via the damaged skin by ecto-parasitic protozoan mainly *Trichodina* sp. and finally results in ulceration. Histologically the ulcerated fish showed extensive lesions, cellular infiltration, necrosis of muscular tissue, sarcolysis, inflammation and granuloma.

Prior to the initial EUS outbreaks, most countries, in the region had not experienced a fish disease epizootic on such a large scale. There has been a great deal of local apprehension as to the consequences of consuming diseased fish or using affected waters for irrigation or agricultural purposes. The concurrent death of cattle, duck, and other animal attributed to the occurrences of EUS. However, there is no scientific evidence that the disease itself causes any human or animal illnesses.

REFERENCES

1. Ahne, W., P.E.V. Jorgensen, N.J.Olesen, and N.Wattanavijarn. (1988). Serological examination of a rhabdovirus isolated from snakehead (*Ophiocephalu striatus*) in Thailand with ulcerative syndrome. *Journal of Applied Ichthyology*. 4: 194 - 196.
2. Ali, A. and Tamuli. K (1991). Isolation of an etiological agent of epizootic ulcerative syndrome. *Fishing Chimes*. 11:43 - 46.
3. Callinan , R.B., G.C.Fraser, and J.L Virgona. (1989). Pathology of red spot diseases in sea mullet, *Mugil cephalus* L., from eastern Australia. *Journal of Fish Diseases*.12: 349 - 356
4. Callinan, R.B. and J.A. Keep. (1989). Bacteriology and Parasitology of red spot disease in sea mullet, *Mugil cephalus* L. from eastern Australia. *Journal of Fish Diseases*.12: 349-356.

5. Callinan R.B. Fraser, G.C and Virgona, J.L (1989). Pathology of red spot disease in sea mullet, *Mugil cephalus* L from eastern Australia. *Journal of Fish Diseases*.12: 467-479.
6. Chakarabarty A,N. and Dastidar, S.G.(1991). Repeated isolation of chemoautotrophic nocardia form bacteria from fish epizootic syndrome. *Indian Journal of Experimental. Biology*. 29: 623-627.
7. Frerichs G.N. , Millar, J.D. and Roberts R.J.(1986) . Ulcretaive rhabdovirus in fish in South-East Asia. *Nature*. 322: 216.
8. Lilley J.H., Phillips,M.J. and Tonguthai K.(1992). A review of epizootic ulcerative syndrome(EUS) in Asia. Aquatic Animal Health Institute and Network of Aquaculture Centres in Asia and Pacific, Bangkok, Thailand.
9. Llobreraa A.T. and Gacutan R.Q. (1987). *Aeromonas hydrophilla* associated with UD. Epizootic in Laguna de Bay. Phillipines. *Aquaculture*. 67; 273 - 278.
10. Roberts.R.J, Frerichs,G.N.,Tonguthai,K. and Chinabut,S.(1994). Epizootic ulcerative syndrome of farmed and wild fishes. *Recent Advances in Aquaculture*.
11. Roberts R.J. Willoughby L.G and Chinabut S. (1993) Mycotic aspects of epizootic ulcerative syndrome (EUS) of Asian fishes. *Journal of Fish Diseases*. 16:169-183.
12. Vinobaba,P. George, S. T.(1996). An assesment of fishermen welfare in Batticaloa district. This was presented at the Regional workshop on "Research for the management of coastal resources in the tropics." 9th to 10th November 1996.
13. Vinobaba M and Vinobaba P. (1999). Unknown ulcerative disease among commercially important finfish from the Batticaloa lagoon. This was presented to the fifth Annual sessions of Sri Lanka Association for Fisheries and Aquatic Resources : 23 - 24th June 1999. 5: p 10.